

## Awake Craniotomy: An Early Experience in B & B Hospital

**Anish M Singh, MS; Prabin Shrestha, MD, PhD**

Unit of Neurosurgery, Department of Neuroscience, B & B Hospital, Lalitpur, Nepal

### Address for Correspondence:

Anish M Singh, MS

Unit of Neurosurgery, Department of Neuroscience, B & B Hospital, Lalitpur, Nepal

**Email:** anishmsingh@gmail.com

**Received,** 7 April, 2017

**Accepted,** 20 April, 2017

Awake craniotomy is getting popular in developed and developing countries. Even though it is not yet popular in Nepal, it has been being practiced now and then in different hospitals in Kathmandu. Recently it has been introduced in B & B hospital as well by our team and we successfully performed awake craniotomy in 2 cases.

In first case, the awake craniotomy was performed for the brain tumor which was located in the eloquent area of left parietal lobe. In second case the surgery was performed for arteriovenous malformation (AVM) which was located in deep left frontoparietal area.

The aim of awake craniotomy in both the cases was to preserve the motor cortex and thus prevent possible major neurological deficit.

**Keywords:** awake craniotomy, AVM, B & B hospital, brain tumor.

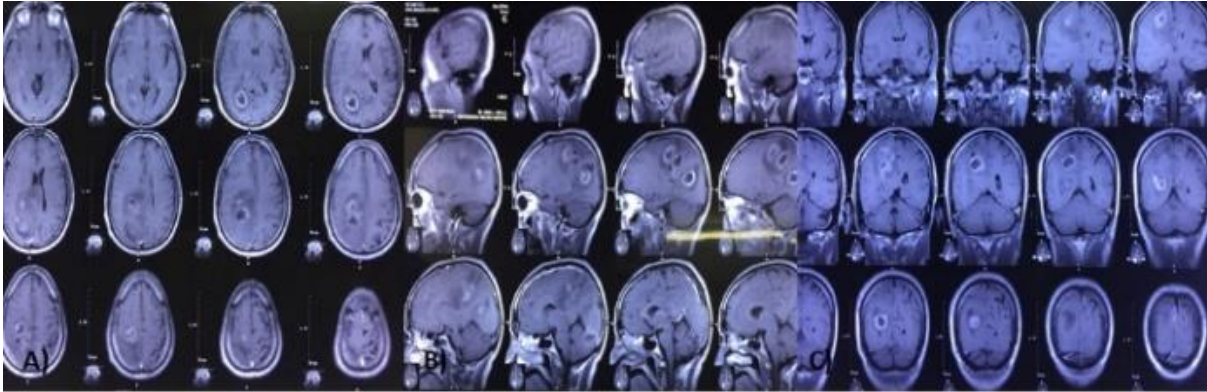
---

**A**wake craniotomy is getting more and more popular in the recent years. It was first started in North America in early 1980s, soon it spread in Europe and now it is getting popular in Asia also.<sup>1</sup> In ancient time, a hole in the skull used to be made in an awake patient believing an evil thing will come out of brain and will relieve the patient.

In modern era, it is mainly indicated in the surgery of lesions located in the dominant hemisphere and in and around the eloquent areas of brain. Awake craniotomy is most commonly performed in epilepsy surgery to remove the epileptic focus safely.<sup>1</sup> In general, lesions located in left

frontotemporal and parietal areas are the most common ones operated by awake craniotomy. By doing awake craniotomy surgical damage to the eloquent area and thus neurological deficits can be avoided or minimized.<sup>2-4</sup> Awake craniotomy also helps to minimize hospital stay and lowers the overall cost.<sup>3,4</sup>

Occasionally awake craniotomy is also indicated in the cases where anesthesia is contraindicated or is highly risky such as severe cyanotic heart disease.<sup>5</sup> During awake craniotomy, the patient's language, motor and sensory functions are identified and examined by neurological testing which requires a fully awake and



*Figure 1: Preoperative contrast enhanced MRI of brain showing multiple enhancing mass lesions in right parietal lobe*

cooperative status of patient. Hence, the anesthesia during awake craniotomy aims for an unconscious patient at the beginning and the end of surgery but an awake and responsive patient in between during examination.<sup>6</sup> For this propofol is regarded as ideal anesthetic agent. This technique is called asleep-awake-asleep (AAA) anesthesia in which patient is first made sleep with anesthetic agents and is awakened in between for neurological examination and then made sleep again at the end of surgery.<sup>7</sup>

## Case Reports

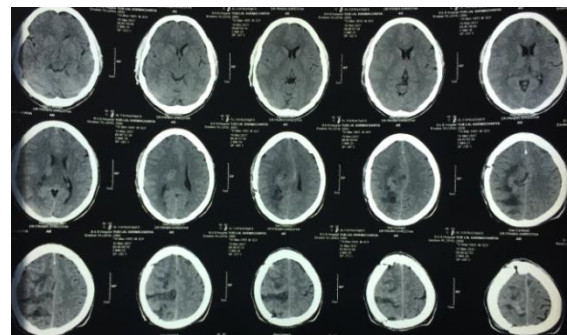
### Case I

A 63-year-old male patient presented with features of raised intracranial pressure such as headache, vomiting, vertigo etc since few weeks back. He also occasionally had speech difficulty and right sided weakness along with seizure like trembling of right limbs. Otherwise he was neurologically stable, could walk around and speak near normally.

His CT scan showed multiple mass, cystic and solid component with significant surrounding cerebral edema in left hemisphere. MRI brain also showed the same findings (**Figure 1**). Considering

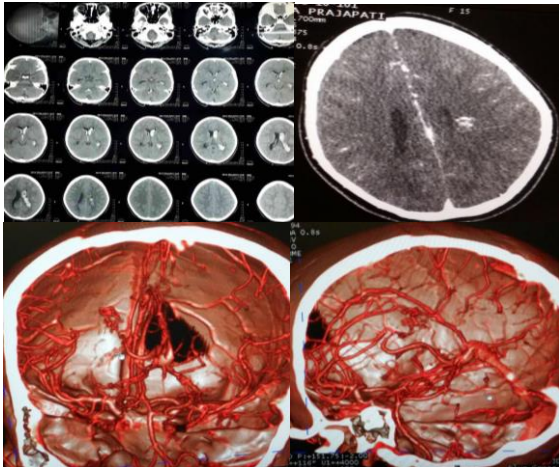
differential diagnosis of cerebral abscess or high grade glioma, surgery was planned. Since the lesions were located in the left parietal area which is the dominant eloquent area of human brain, possibility of complete right hemiplegia and aphasia after surgery was possible which was explained to the patient party.

Awake craniotomy was planned and accordingly the case was discussed with the team of anesthetist. Sleep-awake-sleep technique was planned. Accordingly patient was intubated and general anesthesia was induced. Before that, lignocaine was injected at the sites of three pins of three pin head holder and also circumferentially in the whole head to avoid scalp pain during surgery.



*Figure 2: Postoperative CT scan of brain showing gross resection of lesions*

Muscle relaxant was not added afterwards. Craniotomy was performed and dura was opened in about 45 minutes. Propofol infusion was started for analgesia and sedation. Before doing corticotomy, brain surface was stimulated with the low voltage of bipolar to see if there is any motor response in the limbs so that we can mark the safe area for corticotomy.



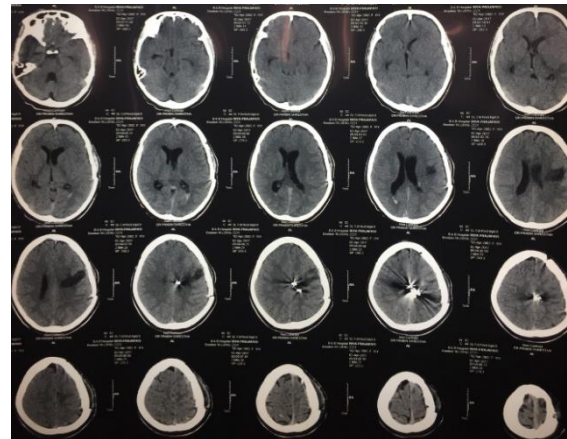
*Figure 3: Preoperative images, A) CT scan of brain showing intraventricular hemorrhage in bilateral lateral ventricles with early hydrocephalus, B) Contrast CT scan showing ArterioVenous Malformation (AVM) in left parietal lobe, C & D) CT angiography showing AV*

Similarly, while doing corticotomy and resection of the mass, painful stimulus was given in all the limbs to see the motor function. Bilateral painful stimulation facilitated the comparison of motor response on both sides. When the motor response became weaker on the right side, corticotomy and mass resection was avoided in that location of left cerebral hemisphere. Speech and motor response of the patient to the verbal command couldn't be assessed as patient was intubated with usual endotracheal tube which was not extubated during awake state due to some technical difficulty. Moreover patient

couldn't be made really light during surgery to make him understand our verbal command. When patient was light dose of propofol had to be increased to sedate the patient. We controlled dose of propofol manually as we don't have device to set the target dose of propofol.<sup>7</sup>

After completing the mass resection, patient was resedated with usual anesthetic agents and muscle relaxants and surgery was completed.

Patient was fully conscious and neurologically nearly intact after surgery. He could speak and walk normally and was discharged within one week of surgery. Postoperative CT scan showed near total resection with small residual mass (**Figure 2**). His biopsy revealed high grade glioma, glioblastoma multiformes (GBM).



*Figure 4: Postoperative CT scan of brain showing resection of AVM and clip artifacts in left frontoparietal area*

### **Case II**

A 15-year-old girl presented with emergency with severe headache, vomiting and loss of consciousness. Thorough investigation revealed small arteriovenous malformation (AVM) in left parietal lobe in deep subcortical area just lateral to the lateral wall of left lateral ventricle (**Figure 3**).

Since the lesion was deeply located in eloquent area of dominant hemisphere, possibility of speech difficulty and right sided motor deficit after surgery was very high which was explained to patient party. The whole anesthetic procedure was performed as in case of illustration I. After surgery, the girl remained semiconscious and right spastic hemiparetic for first few weeks probably due to cerebral ischemia while resecting AVM sacrificing feeders and small perforators. Speech also improved with improvement in the conscious level and was finally discharged after about 1.5 month of surgery. Her postoperative CT scan revealed resection of the AVM and clip artifacts at the site of previous AVM (**Figure 4**). Biopsy revealed AVM.

### Discussion

The anesthetic challenge of awake craniotomy is to maintain adequate sedation, analgesia, respiratory and hemodynamic stability in an awake patient who should be able to cooperate during intraoperative neurological assessment. Therefore this is more of an anesthetic technique rather than a neurosurgical.<sup>8</sup>

Awake craniotomy can be performed and is indicated in various conditions. Surgery involving dominant and eloquent part of the brain is the most common indication. In addition, other conditions other than brain itself such as heart and other conditions which can be contraindication to the general anesthesia, awake craniotomy is indicated. Brain surgery with awake craniotomy is already an established technique in highly developed countries. In the country like ours also it has been occasionally practiced

with fairly good result though not completely successful.

In B & B hospital awake craniotomy is not yet a routine procedure due to various factors. Therefore the above mentioned cases are our initial experience in this field in neurosurgery.

Wada test, to find the dominance and speech function of the cerebral hemisphere, was not done in our cases before surgery as it is not yet available in Nepal.

Similarly patient and patient party were briefly explained about the procedure of awake craniotomy. Detail procedure was not explained as medical community and general public in Nepal are not yet that familiar with the technique of awake anesthesia and detail explanation about this procedure may create confusion in patients and they may refuse the process. With our own better experience in this field we might be able to explain well to patients and persuade them well in future. Ruis C et al have shown that significant anxiety develops in patients planned for awake craniotomy.<sup>9</sup> They have shown that females and younger patients are more vulnerable in this matter. However, other studies have shown that there is no or minimal psychological impact on the patient because of awaking in the middle of surgery.<sup>10</sup>

Similarly, functional MRI of brain and tractography couldn't be performed as it is not yet available in Nepal. Could it have been done, it would have been much easier to demark the lesion from dominant and eloquent part of brain.

Intraoperative neurophysiological monitoring such as motor evoked potential (MEP), somato sensory evoked potential (SSEP) etc could also not be done due to its lacking in Nepalese context. MEP, SSEP

could easily show the brain stimulation which we want to preserve or which we want to resect.

In case of case I, the lesions were directly over the motor cortex. There was significant chance of injuring motor cortex by doing corticotomy and resection of mass blindly. So we chose awake craniotomy to avoid motor deficit after surgery. As a result there was no significant neurological deficit after surgery.

Case II was a case of small AVM in deep brain tissue for which significant corticotomy had to be done. There was possibility of damaging motor cortex and also speech area while approaching the AVM. Therefore awake craniotomy helped to preserve the motor area.<sup>11</sup>

Propofol along with fentanyl was used for awakening and adequately sedating the patient during awake craniotomy in both cases which was very helpful for maintaining analgesia and anesthesia.<sup>6,8</sup>

Despite having all the limitations, not only in B & B hospital but also in Nepal as a whole, we attempted to perform this relatively newer technology in our hospital to invent our own technology and practice in Nepalese context.

We can learn technology but we cannot directly import it. We have to devise it in our own context.

## References

1. July J, Manninen P, Lai J, Yao Z, Bernstein M. The history of awake craniotomy for brain tumor and its spread into Asia. *Surg Neurol* 2009;71:621-4.
2. Groshev A, Padalia D, Patel S, Garcia-Getting R, Sahebjam S, Forsyth PA et al. Clinical outcomes from maximum-safe resection of primary and metastatic brain tumors using awake craniotomy. *Clin Neurol Neurosurg* 2017;157:25-30.
3. Eseonu CI, Rincon-Torroella J, ReFaey K, Quiñones-Hinojosa A. The Cost of Brain Surgery: Awake vs Asleep Craniotomy for Periolandic Region Tumors. *Neurosurgery* 2017. [Epub ahead of print]
4. Eseonu CI, Rincon-Torroella J, ReFaey K, Lee YM, Nangiana J, Vivas-Buitrago T et al. Awake Craniotomy vs Craniotomy Under General Anesthesia for Periolandic Gliomas: Evaluating Perioperative Complications and Extent of Resection. *Neurosurgery* 2017. [Epub ahead of print]
5. D'Antico C, Hofer A, Fassl J, Tobler D, Zumofen D, Steiner LA et al. Case Report: Emergency awake craniotomy for cerebral abscess in a patient with unrepaired cyanotic congenital heart disease. *F1000Res*. 2016;5:2521.
6. Soehle M, Wolf CF, Priston MJ, Neuloh G, Bien CG, Hoeft A et al. Propofol Pharmacodynamics and Bispectral Index During Key Moments of Awake Craniotomy. *J Neurosurg Anesthesiol* 2016. [Epub ahead of print]
7. Wang X, Wang T, Tian Z, Brogan D, Li J, Ma Y. Asleep-awake-asleep regimen for epilepsy surgery: a

- prospective study of target-controlled infusion versus manually controlled infusion technique. *J Clin Anesth* 2016;32:92-100.
8. Sokhal N, Rath GP, Chaturvedi A, Dash HH, Bithal PK, Chandra PS. Anaesthesia for awake craniotomy: A retrospective study of 54 cases. *Indian J Anaesth* 2015;59:300-5.
  9. Ruis C, Wajer IH, Robe P, van Zandvoort M. Anxiety in the preoperative phase of awake brain tumor surgery. *Clin Neurol Neurosurg* 2017 ;157:7-10.
  10. Riquin E, Dinomais M, Malka J, Lehouste T, Duverger P, Menei P et al. Psychiatric and psychological impact of surgery while awake in children for resection of brain tumors. *World Neurosurg* 2017. [Epub ahead of print]