

## Cerebral Aneurysm Surgery in B & B hospital: An Experience of Last One Year

Prabin Shrestha<sup>1</sup>, MD, PhD; Anish M Singh<sup>1</sup>, MS; Isha Dhungana<sup>2</sup>, MD, PhD

<sup>1</sup>Unit of Neurosurgery, Department of Neuroscience, B & B Hospital, Gwarko, Lalitpur, Nepal

<sup>2</sup>Unit of Neurology, Department of Neuroscience, B & B Hospital, Gwarko, Lalitpur, Nepal

### Address for Correspondence:

Prabin Shrestha, MD, PhD

Unit of Neurosurgery, Department of Neuroscience, B&B Hospital, Gwarko, Lalitpur, Nepal

**Email:** prabinshrestha@hotmail.com

**Received,** 12 May, 2017

**Accepted,** 23 May, 2017

Aneurysm surgery is one of the common surgical procedures all over the world, so is in Nepal. Though a common surgical procedure, aneurysm surgery is regarded as a high-tech surgery as it requires significant technology in terms of both hospital facilities and the skill of an operating surgeon. Successful aneurysm surgery in any hospital reflects an established and successful neurosurgery.

Aneurysm surgery has become a routine surgery in B & B hospital as well.

This is a retrospective case series analytical study.

Total 9 cases of cerebral aneurysms were operated in one year period in the years 2016 and 2017. Different locations of aneurysm were anterior communicating artery (AComA), middle cerebral artery bifurcation (MCA), posterior communicating artery (PComA) and MCA trunk (M1).

Females were more common than males and age ranged from 35 to 60 years.

All the cases presented with diffuse sub arachnoid hemorrhage. Cases according to Hunt and Hess grading (HH) were 1 was HH grade V, 1 was HH grade IV and 7 were HH grade III.

All the patients with HH grade III survived after surgery. Patient with HH grade IV was critically ill after surgery and was in ICU for long period. She was shifted to another hospital due to financial reason and finally survived and discharged. Patient with HH grade V expired after surgery.

In conclusion, aneurysm surgery has been established in B & B hospital with good and satisfying outcome.

**Keywords:** aneurysm surgery, B & B hospital, outcome.

---

**A**neurysm surgery is one of the common surgical procedures all over the world, so is in Nepal.

Though a common surgical procedure, aneurysm surgery is regarded as a high-tech surgery as it requires significant technology

in terms of both hospital and the operating surgeon.<sup>1,2</sup> Successful aneurysm surgery in any hospital reflects an established and successful neurosurgery.

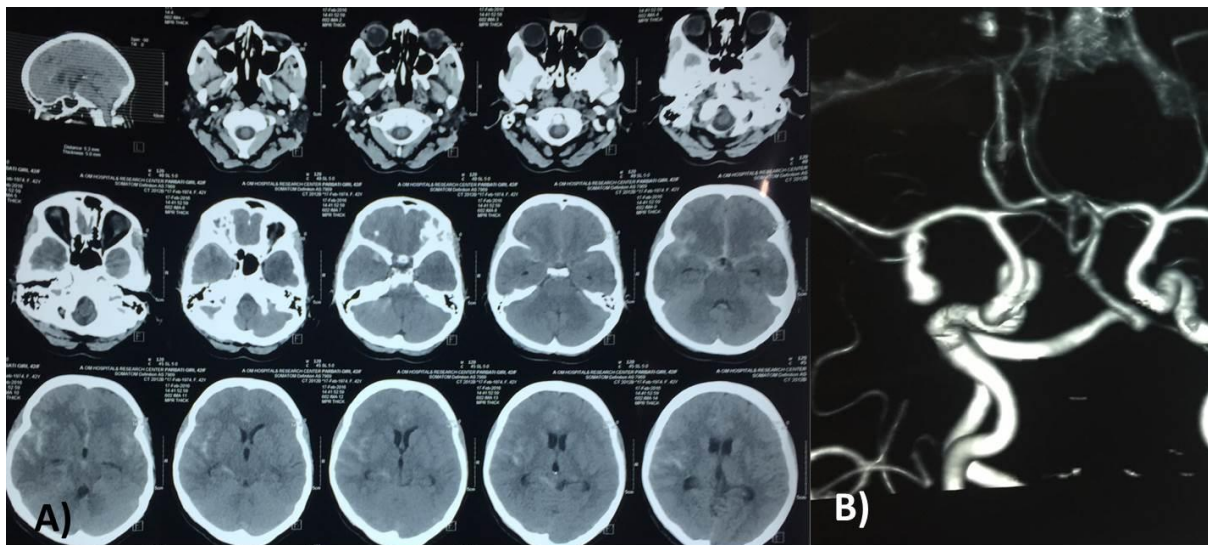
There are mainly two modalities of cerebral aneurysm treatment; they are surgical clipping and endovascular coiling.<sup>3</sup> Both the techniques are equally good and both of them have pros and cons. None of them are superior to each other, rather each of them supplement each other many a times. However, in developing and poorly developed countries like Nepal, coiling is not yet started as it is technically much different and difficult and moreover, it is highly costly as compared to open surgical clipping. Nevertheless, it will and it has to be started and established in our country in near future.

ultra-early clipping and, if not, early clipping is the best policy.<sup>4</sup>

### Materials and Methods

The cases in this study were those operated in one year period in 2016 and 2017 in B & B hospital. Altogether 9 cases of non-traumatic SAH presented in emergency, were admitted in ICU and were thoroughly evaluated. Cerebral aneurysm was detected in all the cases. Open craniotomy and aneurysm clipping was planned.

Two cases, cases with HH grade IV and V, had features of massive rise in intracranial pressure (ICP) with intracerebral hematoma and early hydrocephalus. They were operated on emergency basis as they were neurologically critical and needed decompressive craniotomy and evacuation



*Figure 1: Preoperative images of the first aneurysm surgery case, A) pre-operative CT scan showing SAH more in the right sylvian fissure, B) CT angiography of brain showing elongated aneurysm in right MCA bifurcation*

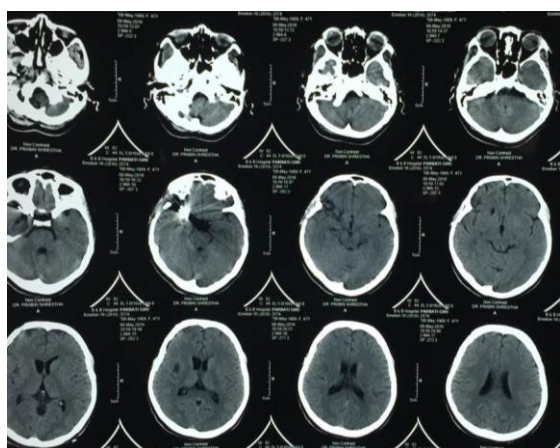
Surgical clipping of aneurysm has to be done as early as possible after presentation. Though there is a trend of avoiding clipping after 48 hours till 2 weeks after subarachnoid hemorrhage (SAH), trend of

of hematoma in addition to aneurysm clipping. Rest of the cases were operated electively, craniotomy and clipping of aneurysm was done within 2-3 days of presentation. **Figure 1** shows a case of the

first aneurysm surgery performed in B & B hospital in 2016. All the cases were operated via pterional approach, mainly on right side otherwise left. A retrospective case series analysis was done and outcome and feasibility of aneurysm surgery in B & B hospital was assessed.

### Results

Of 9 cases, 6 cases were female and 3 were male. Cases ranged from 35 to 60 years in age. Seven cases had HH grade III, one had HH grade IV and remaining one had HH grade V at the time of presentation. CT angiography was done in all the cases with 16 slice CT scanner and ruptured aneurysm was detected in all the cases. Five cases had aneurysm at Anterior Communicating Artery (ACoMA), 2 had aneurysm in MCA bifurcation, one case had PComA aneurysm and one had huge aneurysm in right MCA trunk (M1 segment). **Figure 2** shows aneurysm clipping without any complications. All the cases with HH grade



*Figure 2: Post-operative CT scan showing clip in the right sylvian region*

III survived after surgery. They were observed in ICU for first few days after surgery and then were shifted to general ward. The case with HH grade IV was still very critical after surgery and was in ICU

for few weeks. She was shifted to another hospital, nearby medical college, due to financial reason where she was followed up by one of our team member neurosurgeons. She finally survived, cranioplasty was done by replacing bone flap and discharged. Patient with HH grade V was very critical and didn't improve despite decompressive craniotomy and lobectomy and expired after few days of surgery.

All the cases of HH grade III were neurologically intact after surgery except for few cases who initially had mild hemiparesis and speech difficulty. The case with HH grade IV didn't turn up for FU after discharge.

Average hospital stay was about 6 days, ranged from 4-10 days including 1-2 days of ICU stay.

There was no significant morbidity or post-operative complications in majority of cases.

### Discussion

Intracranial aneurysm is one of the common and critical neurosurgical problem. As in other parts of the world it is common in Nepal also. Though there is no exact data it is estimated that there are about 300000 cases of intracranial aneurysms every year in Nepal and 6000 of them present with rupture and subarachnoid hemorrhage.<sup>1</sup>

In Nepalese context almost all aneurysm are ruptured ones as we don't have system of screening for cerebral aneurysms. Surgical management of unruptured aneurysm is much easier than ruptured ones due to multiple factors.<sup>5</sup> All the aneurysms that we operated so far were ruptured ones, nevertheless the result of surgical clipping is excellent in our experience.

Aneurysm surgery is a high-tech surgery

needing sufficient experience and surgical skill. Therefore aneurysm surgery is not yet a regular surgery in many parts of the world. It is more so in the country like Nepal, where there are no adequate neurosurgeons, hospitals with neurosurgical facilities and over all neurosurgical technology. Despite having these limitations neurosurgeons in Nepal have shown the capability of promptly doing aneurysm surgery. Many hospitals in Kathmandu have skilled neurosurgeons and good neurosurgical facilities. However, hospitals outside Kathmandu, except few, have limited neurosurgical facilities. Difficulty in patient's accessibility to hospitals, lack of proper referral system etc are other few great limitations in aneurysm surgery in Nepal.

B & B hospital is one of the few tertiary care centers of Nepal where major medical services including critical care and neurosurgical care are available. There are almost all facilities for all the neurosurgical procedures. Microneurosurgery is a common procedure in this hospital. So has become the intracranial aneurysm surgery in this hospital.

Aneurysm surgery has developed significantly over the past two decades. Surgical clipping is the main treatment of choice for intracranial aneurysm. In addition coiling, which is an endovascular technique, is also getting more and more popular in highly developed countries. In the countries like Nepal technology of endovascular surgery and coiling has not yet developed. Therefore surgical clipping is the only option we have in Nepal. In many countries including highly developed countries surgical clipping is main modality of aneurysm treatment.<sup>3,6,7</sup>

Complications of both the techniques have reduced significantly as compared to previous years.<sup>2</sup> As a result our experience is also getting better. Only one out of 8 cases that we operated in last one year expired due to very poor pre-operative neurological status. All the other cases survived and went back home with almost intact neurological status.

Thorough arachnoid membrane dissection is an important surgical step in aneurysm surgery. It helps in cerebrospinal fluid (CSF) drain and is helpful for controlling intracranial pressure (ICP). Similarly opening of lamina terminalis helps in draining intraventricular CSF and thus lowers the possibility of future hydrocephalus.<sup>8</sup> In our practice we often dissect all the arachnoid membranes around the basal and prechiasmatic cistern and drain CSF as much possible before dissecting around the aneurysm. We also routinely perform fenestration of lamina terminalis to open the third ventricle after clipping of aneurysm, and thus we have very low frequency of post-operative hydrocephalus.

Surgical clipping of an aneurysm is usually done as early as possible after presentation. Subarachnoid hemorrhage induced vasospasm starts from 48 hours after rupture and becomes severe for about 2 weeks. Therefore early surgery is better. However, clipping can be and should be done at any time after presentation soon after presentation. Early aneurysm clipping not only helps in patient survival but also helps to reduce the total cost of treatment.<sup>4</sup> Our practice in our hospital is early clipping whenever possible. Late clipping, clipping after 2 weeks, is usually not a practice in our hospital. As a result we have hardly any

case of significant post SAH or post-operative vasospasm.

Various medications and techniques have been used to prevent vasospasm during surgical clipping of aneurysm. Papaverine, Clazosentan etc have been found to be quite helpful to prevent vasospasm.<sup>9</sup> However, these medications are not available in Nepal. Despite having lack of these medications we have been able to prevent vasospasm by improved surgical skill and better post-operative critical care.

Readmission and re-surgery of the patient after surgical clipping of aneurysm is expected. It happens everywhere.<sup>10</sup> In our experience so far we don't have any experience of readmission or re-surgery of the patient probably due to our smaller experience or also due to our better management.

Intraoperative neurophysiological monitoring is a very important technique to prevent cerebral ischemia mainly during temporary clipping of parent artery. It is also useful to detect inadvertent clipping of normal artery while putting permanent clip around the neck of aneurysm. It helps to detect the ischemia and thus prevents future cerebral infarction.<sup>11,12</sup> Even though we don't have this technology available in Nepal and in our hospital, we have been able to preserve the normal arteries and perforators and thus to prevent the infarction.

### References

1. Gopal R Sharma, Prashant Kaushal, Rajiv Jha, Nilam Khadka, Dhruva R Adhikari, Prakash Bista et al. Outcome of Microsurgical Clipping of Intracranial Aneurysms in Bir Hospital. Nepal Journal of Neuroscience 2011;8:137-42.
2. Hammer A, Steiner A, Kerry G, Ranaie G, Baer I, Hammer CM et al. Treatment of ruptured intracranial aneurysms yesterday and now. PLoS One 2017;3:e0172837.
3. Fotakopoulos G, Tsianaka E, Fountas K, Makris D, Spyrou M, Hernesniemi J. Clipping versus coiling, in anterior circulation ruptured intracranial aneurysms: A meta-analysis. World Neurosurg 2017 May. [Epub ahead of print]
4. Sonig A, Shallwani H, Natarajan SK, Shakir HJ, Hopkins LN, Snyder KV et al. Better Outcomes and Reduced Hospitalization Cost are Associated with Ultra-Early Treatment of Ruptured Intracranial Aneurysms: A US Nationwide Data Sample Study. Neurosurgery 2017 May. [Epub ahead of print]
5. Walendy V, Stang A. Clinical management of unruptured intracranial aneurysm in Germany: a nationwide observational study over a 5-year period (2005-2009). BMJ Open 2017;7:e012294.
6. Kurogi R, Kada A, Nishimura K, Kamitani S, Nishimura A, Sayama T et al. Effect of treatment modality on in-hospital outcome in patients with subarachnoid hemorrhage: a nationwide study in Japan (J-ASPECT Study). J Neurosurg 2017 May. [Epub ahead of print]
7. Zhao J, Lin H, Summers R, Yang M, Cousins BG, Tsui J. Current Treatment Strategies for Intracranial Aneurysms. Angiology 2017 Jan. [Epub ahead of print]
8. Thiarawat P, Jahromi BR, Kozyrev

- DA, Intarakhao P, Teo MK, Choque-Velasquez J et al. Microneurosurgical Management of Posterior Communicating Artery Aneurysm: A Contemporary Series from Helsinki. *World Neurosurg* 2017;101:379-88.
9. Fujimura M, Joo JY, Kim JS, Hatta M, Yokoyama Y, Tominaga T. Preventive Effect of Clazosentan against Cerebral Vasospasm after Clipping Surgery for Aneurysmal Subarachnoid Hemorrhage in Japanese and Korean Patients. *Cerebrovasc Dis* 2017 May. [Epub ahead of print]
10. Dasenbrock HH, Smith TR, Rudy RF, Gormley WB, Aziz-Sultan MA, Du R. Reoperation and readmission after clipping of an unruptured intracranial aneurysm: a National Surgical Quality Improvement Program analysis. *J Neurosurg* 2017. [Epub ahead of print]
11. Spina A, Mortini P. Intraoperative Neuromonitoring Strategies for Temporary Clipping in Aneurysm Surgery. *World Neurosurg* 2017;101:773-5.
12. Joo SP, Kim TS. The Clinical Importance of Perforator Preservation in Intracranial Aneurysm Surgery: An Overview with a Review of the Literature. *Chonnam Med J* 2017;53:47-55