

Antegrade Flexible Ureterorenoscopy: A Novel Technique in Difficult Times

Rajesh Batajoo, MS; Sumeet Karna, MBBS; Jagdish L Baidya, FRCS, FCPS
Department of Urology, B&B Hospital, Gwarko, Lalitpur, Nepal

Address for Correspondence:

Sumeet Karna, MBBS

Department of Urology, B&B Hospital, Gwarko, Lalitpur, Nepal

Email: sumeetkarna@gmail.com

Received, 9 April, 2017

Accepted, 19 April, 2017

We describe a case of 34-year-old male with stone in unilateral complete duplex ureter associated with hematuria; the challenges that we faced during removal; and how we improvised and managed to remove the stone successfully using novel technique of antegrade ureteroscopy through percutaneous access-sheath tract. We hope the lessons that we learned might be useful to any urologist in a similar situation.

Keywords: antegrade ureteroscopy, duplex ureter, hematuria, ureteric stone.

Ureteral duplication is the most common renal abnormality occurring in 0.8% of the population.¹ Generally in complete duplex ureters, the ureter draining the upper moiety opens more caudally to the lower moiety ureteral opening as described by Weigert-Meyer and Mackie-Stephens' rule. Also, the distal opening (from upper moiety) is generally ectopic and stenotic type whereas the proximal opening (from lower moiety) is orthotopic and refluxing type.^{2,3}

Retrograde ureteroscopy is considered whenever intervention is required for removing stone in middle and lower ureter. But, in cases where access to the ureter is not successful, antegrade ureteroscopy can save the day.

Case Report

A 34-year-old gentleman from Bhaktapur was referred to our department for

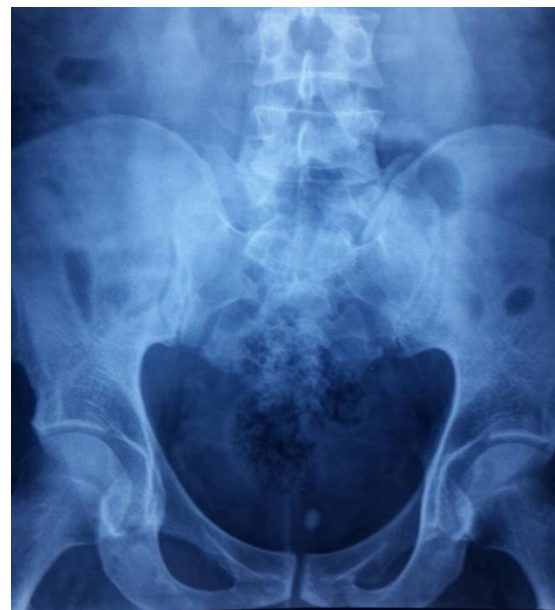

Figure 1: X-ray of pelvis showing radio-opaque shadow at pelvis region

management of left distal ureteric stone in complete duplex ectopic ureter. Patient had on & off visible hematuria as the only complaint. The X-ray KUB (**Figure 1**) showed a radio-opaque shadow at the pelvis.

USG KUB done at the same time showed complete duplex collecting system of left kidney with hydroureteronephrosis of upper moiety with distal opening possibly in prostatic urethra and a large obstructing calculus of about 12mm at the junction.

CT IVU was done to further delineate the anatomy of the ureter (**Figure 2**). The parenchymal thickness of the left kidney appeared to be preserved.

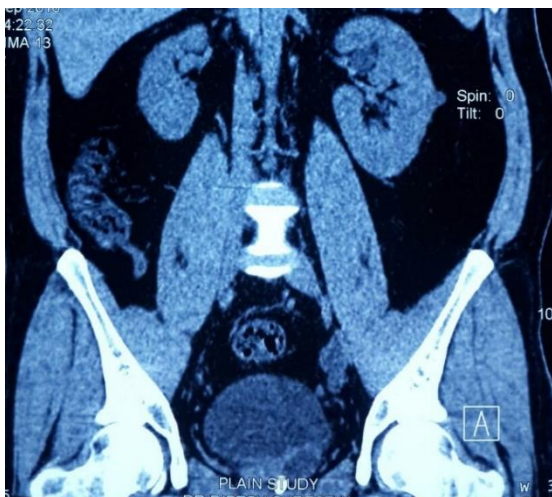

Figure 2: Initial non-contrast CT KUB film showing hyperdense shadow in prostatic urethra, dilated upper moiety of left kidney. The parenchyma of left kidney however, appears normal

Description of Intervention

Patient was planned for ureteroscopic removal of stone after confirmation of negative urine culture. Pre-operative antibiotics was given according to hospital protocol. General anesthesia was given and patient kept in lithotomy position with adequate padding of all pressure points.

Initial cystoscopic evaluation was done using 17F Karl Storz rigid cystoscope and 30° Hopkins Lens. Left ureteric opening from lower moiety was visualized at the superolateral aspect of the trigone.

However, the ureteric opening from the upper moiety that was supposedly opening into the prostatic urethra could not be visualized. However, the stone could be felt on digital rectal examination and visualized under C-arm image intensifier (**Figure 3 A, B**).

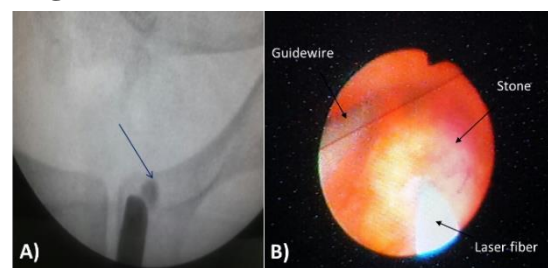


Figure 3: Intraoperative pictures, A) stone visualized at distal ureter opening into prostatic urethra (lateral to cystoscope under C-arm image intensifier), Stone (in black color) indicated by arrow, B) showing Laser fragmentation under process using 200nm fiber and Power at 10 Joules

After non-visualization of ureteric opening in cystoscopy, patient was changed to prone position. Percutaneous puncture of the upper moiety of left kidney was done through upper calyx with ultrasound guidance. Under image intensifier, 20ml diluted contrast agent was pushed and anatomy of the ureter confirmed and the contrast agent was traced into the urinary bladder. 0.035 inch soft tip hydrophilic Terumo guidewire was passed through it into the upper moiety ureter. Then, serial dilatation of the percutaneous tract was done upto 12F and access sheath placed into the upper moiety (**Figure 4**).

Flexible ureteroscope was inserted through the access sheath and stone at the distal ureter visualized. Laser fragmentation (**Figure 3B**) was initiated but it was ergonomically very challenging due to long redundant part of access sheath outside, and position of the stone at distal end.

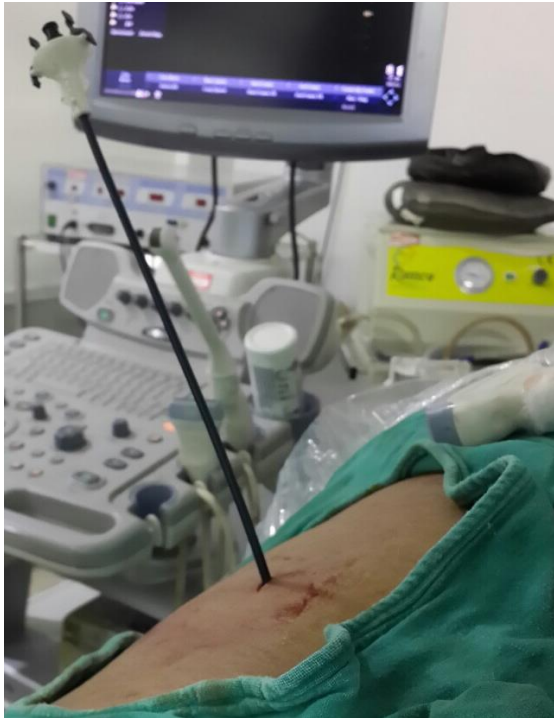

Figure 4: Placement of 9F access sheath after dilatation

After the stone was partially fragmented, it became very mobile and targeting the stone became troublesome. So, flexible ureteroscope along with access sheath was removed after negotiating the guidewire through the ureteric opening and delivered through the urethra.

Patient was again changed to lithotomy position. This time, the semi-rigid ureteroscope could be negotiated through the ureteric opening over guidewire. Remaining stone was pulverized with Laser and double J stent was placed over the guidewire.

Postoperatively patient was discharged on

next day. He had no fever or incontinence. Double J stent removed after 2 weeks. Urine routine done on follow-up showed no hematuria and X-ray KUB confirmed stone clearance.

Discussion

Currently, there are various treatment modalities such as medical expulsive therapy, shock wave lithotripsy (SWL), retrograde ureteroscopy, and laparoscopic and open ureterolithotomy for the treatment of ureteral calculi.⁴ Over the decades, rigid ureteroscopy has established itself as superior to other interventions for removal of distal ureteric stone.⁵ However there are situations in which retrograde ureteroscopy is not possible such as in case of ureteric stricture, cross-trigonal ureteric re-implantation, urinary diversions, distal ureteric malformations, renal transplant,⁶ selected cases of paediatric male child. In such cases, retrograde ureteroscopy can provide access to the system as well as provide a means of definite treatment. Some studies have used this technique very efficiently in treating stones in ileal conduit ureter as well as treating ureteric strictures or possible ureteric tumors with minimal or no complications.^{7,8}

Conclusion

In this age of minimally invasive procedures, it is very essential to equip ourselves with modern endourological armamentarium and device novel use of this in managing unforeseen challenges.

Antegrade ureteroscopy is safe, feasible, effective and should be considered when retrograde access to ureter is difficult or not possible.⁹

References

1. Nation EF. Duplication of the kidney and ureter: a statistical study of 230 new cases. *J Urol* 1944;51:456.
2. Ichikawa I, Kuwayama F, Pope JC, Stephens FD, Miyazaki Y. Paradigm shift from classic anatomic theories to contemporary cell biological views of CAKUT. *Kidney international* 2002;61:889-98.
3. STEPHENS FD. Anatomical vagaries of double ureters. *ANZ Journal of Surgery* 1958;28:27-33.
4. Kim BS, Lee JN, Choi JY, Park YK, Kim TH. Antegrade flexible ureteroscopy for bilateral ureteral stones in a patient with severe hip joint ankylosis. *Korean journal of urology*. 2010;51:800-2.
5. Preminger GM, Tiselius HG, Assimos DG, Alken P, Buck AC, Gallucci M et al. 2007 Guideline for the management of ureteral calculi. *European urology* 2007;52:1610-31.
6. Rhee BK, Bretan PN, Stoller ML. Urolithiasis in renal and combined pancreas/renal transplant recipients. *The Journal of urology* 1999;161:1458-62.
7. Fernandez Gonzalez I, Aguilera Bazan A, Espinales Castro G, Rodriguez Garcia N, Pascual Mateo C, Garcia Mediero JM et al. Diagnostic antegrade ureteroscopy of the upper urinary tract in the orthotopic neobladder. *Archivos espanoles de urologia* 2005;58:139-44.
8. Winter M, Lynch C, Appu S, Kourambas J. Surgery illustrated--focus on details: Access sheath-aided percutaneous antegrade ureteroscopy; a novel approach to the ureter. *BJU international* 2011;108:620-2.
9. Gupta R, Manohar T, Desai MR. Antegrade flexible ureteroscopy in supine position for impacted multiple ureteric calculi. *Indian Journal of Urology* 2006;22:139.