

## Diastematomyelia: A Case Report on A Rare Spinal Dysraphism

**Shanta Thapa, MBBS; Madan Bajagain, MBBS; Anoj Rajkarnikar, MBBS; Anish M Singh, MBBS, MS; Prabin Shrestha, MD, PhD**

Unit of Neurosurgery, Department of Neuroscience, B & B Hospital, Gwarko, Lalitpur, Nepal

### Address for Correspondence:

Prabin Shrestha, MD, PhD

Unit of Neurosurgery, Department of Neuroscience, B & B Hospital, Gwarko, Lalitpur, Nepal

**Email:** prabinshrestha@hotmail.com

**Received,** 19 November, 2017

**Accepted,** 3 December, 2017

Diastematomyelia is a rare congenital anomaly that results in the “splitting” of the Spinal Cord in a longitudinal (sagittal) direction. The signs and symptoms of diastematomyelia may appear at any time of life, although Pre-natal ultrasound diagnosis of this anomaly is usually possible, thus allowing for early surgical intervention and have a favorable prognosis.

We present a case of 12 years old female presented with back pain and scoliotic changes at mid dorsal region since one and half year. There was no associated neurological deficit. Her MRI (Magnetic Resonance Imaging) scan and CT scan of spine showed split spinal cord at D4-5 level.

Surgery was done to remove bony spur and reconstruct the dura around the two separated cords.

**Keywords:** congenital anomaly, diastematomyelia, surgery.

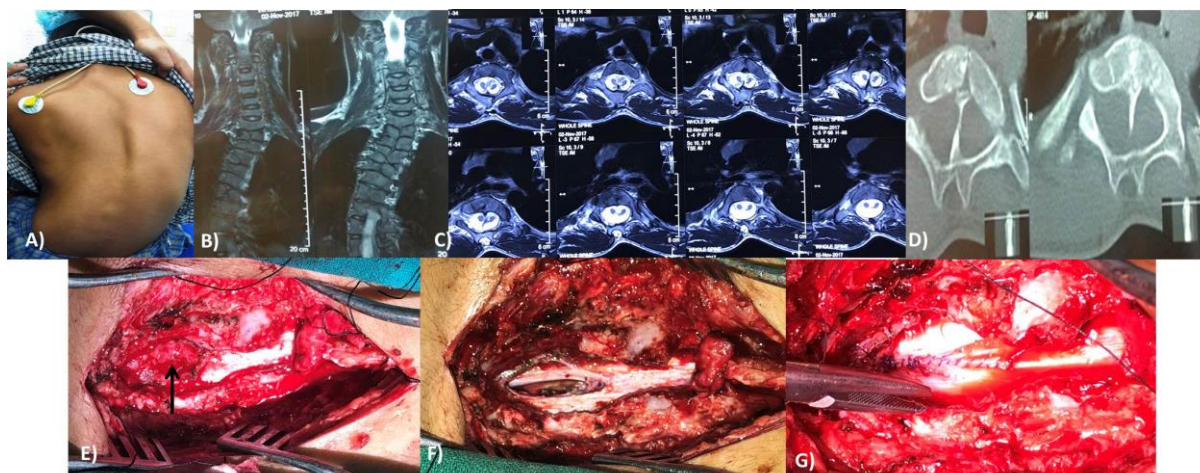
---

**D**iastematomyelia is a rare congenital anomaly that results in the "splitting" of the Spinal Cord in a longitudinal (sagittal) direction. When the split does not reunite distal to the spur, the condition is referred to as a Diplomyelia (which is a "true duplication" of the Spinal Cord).<sup>1</sup> The abnormality most commonly occurs between the T9 and S1 vertebral bodies and is rare within the cervical region.<sup>8</sup> It is more common in

women than men, with some ratios reported as 1.6:1.<sup>9</sup>

### Case Report

A 12-year-old female was referred to our center with complains of back pain and scoliotic changes (**Figure 1**) at mid dorsal region since one and half years. There was no associated limb weakness. She could walk properly with no gait disturbances. Her bowel and bladder habit is normal.



*Figure 1: A) pre-operative picture showing scoliotic deformity of spine, B) MRI T2W coronal image showing scoliosis, C) T2W Axial image showing split spinal cord, D) CT scan axial section showing bony spur within spinal cord, E) Spinal cord and bony spur exposed (arrow), F) split spinal cord after resection of bony spur, G) dural repair and a single spinal cord*

Except for scoliosis there was no neurological deficit. Her birth history and childhood history were uneventful with no birth defects. She had her first menstruation 2 months back.

Her CT Scan of dorsal spine showed D5 hemivertebrae in right side resulting in scoliosis with convexity towards right side, D8 butterfly vertebra, complete bony septum in central spine canal at D4-D5 level and complete block vertebrae involving D1 to D7.

Her MRI SCAN of dorsal spine showed split spinal cord at D4-5 level and widening of spinal canal in upper dorsal level. ECG and Echocardiography were reported normal.

After explaining the possibility of paraplegia and bowel bladder complications, she was planned for surgery. Under GA, in prone position, paravertebral muscle dissection was done and the level D4-5 confirmed with intra-operative C-Arm. Osseous (bony) spur was identified

after laminectomy of D4-5 and it was removed with the help of high speed electric drill under with the microscope. Then durotomy was done, intradural space and spinal cord was thoroughly explored. There were adhesions of spinal cord and nerve roots which were broken with sharp micro scissors. Reconstruction of dural sac was done and single spinal cord was made.

She had no post-operative complications and she started ambulation from the 1st post-operative day. Her presenting complain of back pain was significantly reduced. She was discharged on 4th post-operative day and kept on regular follow up.

### **Discussion**

Diastematomyelia is a rare congenital spinal cord abnormality characterized by longitudinal “splitting up” of the spinal cord into two. Females are affected much more commonly than males. Usually, an osseous (bone), cartilaginous or fibrous septum in the central portion of the spinal canal

produces a complete or incomplete sagittal division of the spinal cord into two hemi cords. Diplomyelia, or true duplication of the spinal cord is said to occur, when the split does not reunite distally to the spur. In this spinal dysraphism, the sagittal cleft may extend in the spinal cord, conus medullaris or even filum terminale and cause splaying of the posterior vertebral elements.<sup>1</sup> Eighty-two per cent of the septa are located between T1 and L5.<sup>2</sup> Split cord malformations are a congenital abnormality and account for about 5% of all congenital spinal defects.<sup>3</sup> Diastematomyelia occurs as a result of abnormal notochord development and abnormal clefting of the spinal canal that cause the cord to split. Initial classification systems described two distinct types of diastematomyelia. The type 1 deformity is characterized by an extradural bony spur that produces two separate dural sacs with two arachnoid sacs for each separate hemicord. This is the type that usually produces symptoms. Likewise, our patient came under this group of classification. Patients are said to have a type 2 diastematomyelia if there is one dural sac surrounding the split cord. While there is no bony spur, these patients can have fibrous septa associated with the split cord. Patients with this type of abnormality are usually asymptomatic.<sup>4</sup> Patients may present with symptoms and progressive neurological deficits suggestive of tethered cord syndrome. Individual symptoms and neurological deficits include back and extremity pain, gait disturbances, bladder and bowel dysfunction, motor

weakness and sensory deficits in the lower extremities, progressive spinal deformity/scoliosis, club foot deformity and sympathetic dystrophy.<sup>2</sup> Cutaneous signs of occult spinal dysraphism are frequently associated with split cord malformation. Hypertrichosis (hairy patch) is the most common manifestation (56%). Capillary hemangioma (26%), dermal sinuses (22%) and subcutaneous lipomas (11%) are also identified with increasing frequency.<sup>5</sup> However, our patient presented with backpain and scoliosis but no neurological deficit.

Currently, CT or MRI is used to confirm the diagnosis. CT scans can show a bony septum and separation of the cord. MRI shows the cord separation and dural sacs in greater detail.<sup>6</sup>

Prenatal ultrasound diagnosis of this anomaly is usually possible in the early to mid third-trimester. An extra posterior echogenic focus between the fetal spinal laminae is seen with splaying of the posterior elements, thus allowing for early surgical intervention and have a favorable prognosis.<sup>7,8</sup> Prenatal or neonatal ultrasound has been used to identify the split cord as well as the echogenic formation which can indicate a bony spur.<sup>9</sup> Asymptomatic patients with diastematomyelia do not require treatment. However, if the patient has symptoms related to the abnormality, they can be treated surgically. Treatment in these patients includes surgery to remove bony spur and reconstruct the dura around the two separated cords.<sup>10</sup>

**Conclusion**

Diastematomyelia is a rare congenital disorder which can be diagnosed early in pregnancy. Patients are often asymptomatic at birth and do not get motor and sensory dysfunction until later in life. Early diagnosis and treatment is important to prevent different kinds of neurological deficits and deformities.

**References**

1. Singh H, Saini M. Diastematomyelia. *Indian J Radiol Imaging* 2000;10:255–7.
2. Pang D, Hoffman H. Split cord malformation. Part II: Clinical syndrome. *Comment. Neurosurgery* 1992;31: 481-500.
3. Özek MM, Maixner WJ. *The Spina Bifida, Management and Outcome*. Springer Verlag. (2008) ISBN:8847006503.
4. Sonigo-Cohen P, Schmit P, Zerah M, Chat L, Simon I, Aubry MC, et al. Prenatal diagnosis of diastematomyelia. *Childs Nerv Syst* 2003;19:555-60.
5. Winter RK, McKnight L, Byrne RA, Wright CH. Diastematomyelia: prenatal

- ultrasonic appearance. *Clin Radiol* 1989; 40: 291-4.
6. Cheng B, Li FT, Lin L. Diastematomyelia: A retrospective review of 138 patients. *The Bone and Joint Journal* 2012; 94: 365-72.
7. Allen LM, Silverman RK. Prenatal ultrasound evaluation of fetal diastematomyelia: two cases of type I split cord malformation. *Ultrasound in obstetrics & gynecology* 2000. 15: 78-82.
8. Banniza von Bazan U, Krastel A, Lohkamp FW. Diastematomyelia - a harmless finding or cause of late neurological disturbance? [Article in German] *Z Orthop Ihre Grenzgeb* 1978;116:72-80.
9. Turgal M, Ozyuncu O, Talim B, Yazicioglu A, Onderoglu L. Prenatal diagnosis and clinicopathologic examination of a case with diastematomyelia. *Congenital Anomalies*. 2013; 53:163-5.
10. Martin K, Krastel A, Hamer J, Banniza UK. Symptomatology and diagnosis of diastematomyelia of children. *Neuroradiology* 1978; 16: 89-90.